Clinical trial

Topical zinc oxide vs. salicylic acid–lactic acid combination in the treatment of warts

Joe A. Khattar, MD, Umayya M. Musharrafieh, MD, Hala Tamim, PhD, and Ghassan N. Hamadeh, MD

From the Department of Family Medicine, and Department of Epidemiology and Biostatistics, Faculty of Health Sciences, American University of Beirut Medical Center, Beirut, Lebanon

Correspondence
Joe A. Khattar, MD
Department of Family Medicine
American University of Beirut
PO Box 11-0236
Beirut
Lebanon
E-mail: jkhattar@cyberia.net.lb

Abstract

Background Warts are a common dermatologic problem. Treatment is painful, prolonged, and can cause scarring.

Objective To evaluate topical zinc oxide for the treatment of warts.

Methods This was a randomized, double-blind controlled trial of 44 patients. Twenty-two patients were given topical zinc oxide 20% ointment, and the other 22 received salicylic acid 15% + lactic acid 15% ointment twice daily. All patients were followed up for 3 months or until cure, whichever occurred first. All patients were observed for side-effects.

Results Sixteen patients in the zinc group and 19 in the salicylic acid–lactic acid group completed the study. In the zinc oxide-treated group, 50% of the patients showed complete cure and 18.7% failed to respond, compared with 42% and 26%, respectively, in the salicylic acid–lactic acid-treated group. No patients developed serious side-effects.

Conclusion Topical zinc oxide is an efficacious, painless, and safe therapeutic option for wart treatment.

Introduction

Warts are a viral skin and mucous membrane infection. They affect both sexes and all age groups. Epidermal cells are infected by direct inoculation. The incubation period varies from 1 to 20 months. Immune-suppressed patients with defects in their cell-mediated immune responses are at higher risk of infection.[1] Patients with genital warts are known to exhibit decreased interleukin-2 and interferon-γ, and a decreased natural killer cell activity.[2] In genital warts, squamous cell carcinoma[3] and carcinoma *in situ*[4] have been reported. Treatment often includes destructive measures,[5–7] which carry a risk of scarring and are painful. Other methods include intralesional bleomycin,[8] fluorouracil,[9] intralesional interferon,[10] and photodynamic therapy.[11]

Salicylic and lactic acids used in combination for a period of 3 months give variable results: 67–84% cure rates.[12] Gibbs *et al.*,[13] in a review, concluded that the best evidence for efficacy was for topical salicylic acid treatment. Spontaneous resolution is also known to occur in warts.

Zinc is known to modulate the immune response. Zinc deficiency causes depression at all levels of the immune system.[14] Al-Gurairi *et al.*[15] treated recalcitrant warts with oral zinc sulfate vs. placebo with 86.9% clearance after 2 months. Mancino *et al.*[16] treated vulvo-perineal human papilloma virus (HPV) infection with topical zinc sulfate and usnic acid. They reported up to 77.6% recovery after 6 months of treatment.

This is a randomized, double-blind clinical trial comparing the cure rates of warts treated with 20% zinc oxide ointment vs. those treated with a combination of 15% salicylic acid and 15% lactic acid over a period of 3 months.

Methods

The study was approved by the institutional research board and was conducted at the American University of Beirut, Beirut, Lebanon. The study extended from February 2005 to December 2005. Patients with warts who signed a consent form were included. The exclusion criteria were as follows: patients under 12 years of age, immunocompromised patients, and those already on treatment for warts. Patients were assigned randomly to two groups. The medication was prepared at our pharmacy and given to patients free of charge in a jar labeled as arm A or arm B. Patients were instructed to apply the medication twice per day, wait for the medication to dry, and to rub the wart with an emery stone before the evening dose. The number of warts was recorded and photographs were taken at the start and every 2 weeks for each patient. The patients were followed up for 3 months or until cure, whichever came first. At the end of the study, the pharmacist informed the primary investigator that arm A was 20% zinc oxide and arm B was the 15% salicylic acid–15% lactic acid combination.

Table 1 Patients on zinc oxide treatment

Age (years)	Sex	Site of lesion	Duration	No. of lesions	Type of lesion	Last week of follow-up	Final cure
26	Female	Fingers	2 years	5	Common	Week 7	Drop
38	Male	Fingers	5 years	3	Common	Week 12	Yes
46	Male	Fingers	1 month	1	Common	Week 10	Yes
20	Female	Periungual	2 months	1	Common	Week 6	Yes
21	Female	Finger	1 week	1	Common	Week 12	No
19	Female	Fingers	2 years	6	Plane	Week 12	Yes
34	Female	Fingers	2 weeks	2	Common	Week 12	Yes
24	Female	Fingers	1 year	3	Common	Week 6	Drop
27	Male	Finger	1 year	7	Common	Week 12	No
42	Male	Fingers	1 week	1	Common	Week 12	Yes
21	Female	Sole	2 months	3	Common	Week 2	Drop
16	Male	Sole	3 months	6	Common	Week 12	No
21	Female	Hands	1 year	7	Common	Week 12	No
28	Male	Lower leg	2 months	2	Plane	Week 12	No
29	Female	Hand	1 month	2	Plane	Week 12	No
27	Female	Hands	2 years	41	Plane	Week 2	Drop
29	Male	Forearm	1 month	15	Plane	Week 12	No
22	Female	Finger	3 months	1	Common	Week 2	Drop
13	Female	Foot	1 month	2	Common	Week 12	Yes
24	Male	Wrist	1 year	1	Plane	Week 12	No
22	Male	Toe	1 year	1	Common	Week 4	Drop
21	Male	Elbow	2 months	2	Plane	Week 6	Yes

Table 2 Patients on salicylic acid–lactic acid combination treatment

Age (years)	Sex	Site of lesion	Duration	No. of lesions	Type of lesion	Last week of follow-up	Final cure
19	Male	Fingers	7 months	15	Common	Week 12	No
20	Female	Foot sole	2 weeks	1	Common	Week 12	No
25	Male	Chin	3 weeks	3	Filiform	Week 4	Yes
23	Female	Fingers	3 years	3	Common	Week 12	No
18	Female	Finger	6 weeks	1	Common	Week 4	Yes
21	Male	Finger & periungual	8 months	3	Common	Week 12	Yes
21	Female	Fingers	7 months	3	Common	Week 6	Yes
21	Female	Elbow	1 year	1	Common	Week 12	No
22	Female	Palm	1 year	2	Common	Week 12	No
19	Male	Fingers	3 months	1	Common	Week 2	Drop
21	Female	Sole	1 month	1	Common	Week 6	Yes
20	Male	Hand	2 months	2	Common	Week 12	Yes
16	Male	Sole	4 months	11	Common	Week 6	Yes
18	Male	Sole	Several months	8	Mosaic	Week 12	No
34	Female	Finger	1 year	2	Common	Week 12	No
18	Male	Palm	1 year	1	Common	Week 12	Yes
22	Male	Foot	7 months	15	Common	Week 4	Drop
21	Male	Lower leg	3 months	1	Common	Week 12	No
22	Female	Soles	6 months	2	Common	Week 12	No
25	Female	Sole	2 months	8	Common	Week 12	No
27	Male	Finger	5 months	1	Plane	Week 12	No
18	Male	Hands & fingers	3 years	10	Common	Week 4	Drop

Results

There were 22 patients in each group (Tables 1 and 2). In the zinc oxide group, six patients dropped out, eight achieved complete cure, four improved up to 50%, one up to 75%, and three showed no improvement. In the salicylic acid–lactic acid group, three patients dropped out, eight achieved complete cure, four improved up to 50%, two up to 75%, and five showed no improvement. The P values were 0.26 and 0.64 for those who dropped out and showed complete cure,

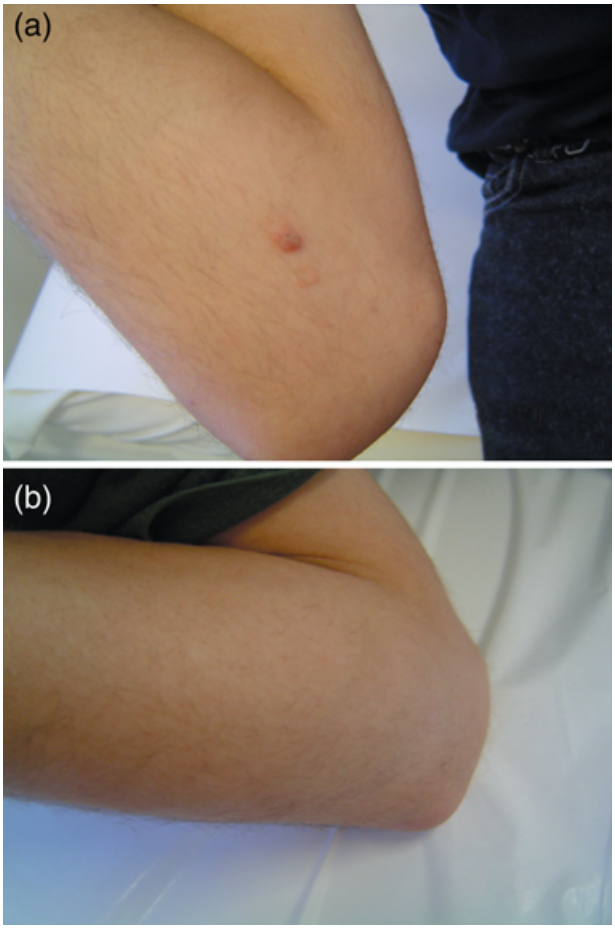

Figure 1 Patient before (a) and after (b) treatment with zinc oxide

respectively. None of the 44 patients switched medications. Figure 1 shows photographs of a patient before and after treatment with zinc oxide.

The distribution of gender, site, number, and weeks of follow-up was similar for both groups; however, the average age of patients who received zinc oxide was significantly higher than those who received the salicylic acid–lactic acid combination (Table 3). Side-effects were mainly local and mild.

Using a Cox regression model in which the dependent variable was final cure and the independent variables were treatment and the age of the patient (as age was significantly associated with treatment), and taking into consideration the time that each patient was followed up, we found that the effect of treatment on time to cure was similar for both groups adjusting for age (odds ratio, 1.04; 95% confidence interval, 0.37–2.97).

Table 3 Patients on zinc oxide and salicylic acid–lactic acid treatment

	Zinc oxide *n* (%) Group A	Salicylic acid–lactic acid *n* (%) Group B	*P*
Age, mean (SD) (years)	25.8 (8.1)	21.2 (3.8)	0.02
Sex			
Male	10 (45.5)	12 (54.5)	0.55
Female	12 (54.5)	10 (45.5)	
Duration (years)			
< 1	13 (44.8)	16 (55.2)	0.34
> 1	9 (60.0)	6 (40.0)	
Number of lesions, mean (SD)	5.1 (8.7)	4.3 (4.6)	0.70
Type of lesion			
Common	15 (44.1)	19 (55.9)	0.07
Plane	7 (87.5)	1 (12.5)	
Filiform	0	1 (100)	
Mosaic	0	1 (100)	
Weeks of follow-up, mean (SD)	9.1 (3.9)	9.3 (3.7)	0.91

Discussion

The treatment of warts is time consuming and expensive. Zinc oxide 20% ointment seems promising and is comparable with 15% salicylic acid combined with 15% lactic acid ointment in the treatment of warts. Half of the patients were cured during 3 months of treatment with no residual scarring and no hypo- or hyperpigmentation. The response in others was partial after 3 months. The side-effects were minimal and included erythema, scaling, and swelling (Table 4). Al-Gurairi *et al.*[15] reported similar symptoms in patients who received oral zinc therapy.

Topical zinc may initiate a cascade of immunologic events. Inflammation induced by zinc, as evidenced by local skin reactions, helps in the recognition of the antigen and alerts T lymphocytes to wart-derived keratinocytes.[17] Macrophages may also be activated by the action of the immune interferon secreted by T lymphocytes.[18]

Imiquimod is known to enhance innate and acquired cellular immunity by inducing the production of cytokines. Edwards *et al.*[19] compared 5% and 1% topical imiquimod cream with placebo in anogenital warts. Their results revealed total clearance in 50% of patients using 5% imiquimod cream, in 21% of patients using 1% cream, and in 11% of the placebo group.

Several uncontrolled clinical trials have implicated hypnotic and nonhypnotic suggestive treatments in the remission of warts.[20] It is possible that zinc treatment may have raised the expectations of patients, but this should have been the same for the salicylic acid–lactic acid group.

Another concern is the penetration of the medication; it is assumed that rubbing the lesion daily with an emery stone can disrupt the keratinized surface, thus helping the penetration of zinc oxide.

Conclusion

Zinc oxide is simple to apply and painless, and therefore may be promising for the treatment of children. Further studies are

Table 4 Patients who developed side-effects during the study period

	Zinc oxide	Salicylic acid–lactic acid	*P* value
Erythema	10 (71.6%) (mild)	17 (100%) (16 mild, 1 moderate)	0.02
Swelling	12 (85.7%) (11 mild, 1 moderate)	5 (29.4%) (mild)	0.004
Scaling	7 (50%) (4 mild, 3 moderate)	14 (82.3%) (mild)	0.004
Itching	None	1 (mild)	0.36
Tenderness	None	1 (mild)	0.36
Blackening	4 (28.6%) (mild)	2 (11.7%) (mild)	0.29
Total patients with side-effects	14 (63.6%)	17 (77.3%)	0.32

needed to clarify the role of zinc. Other methods, such as subcutaneous or intralesional routes, may prove to have a more rapid effect. The period of treatment may need to be extended to improve the results.

References

1 Spencer E, Anderson H. Clinically evident non-terminal infections with wart virus in immunosuppressed renal allograft recipients. *Br Med J* 1970; **1**: 251–254.

2 Tyring SK, Canda R, Grossi CE, *et al.* Patients with condylomata acuminatum exhibit decreased Ilk2 and IFG production and decreased NK cell activity. *J Clin Immunol* 1987; **7**: 304–311.

3 Siegel A. Malignant transformation of condyloma acuminatum. Review of the literature and report of a case. *Am J Surg* 1962; **103**: 613–617.

4 Dawson DF, John K, Duckworth J, *et al.* Giant condyloma and verrucous carcinoma of the genital area. *Arch Pathol* 1965; **79**: 225.

5 Bart B, Biglow J, Vance J, *et al.* Salicylic acid in karaya gum patch as a treatment for verruca vulgaris. *J Am Acad Dermatol* 1989; **20**: 74–76.

6 Erkens AMGL, Kuijpers RJAM, Knottnerus JA. Treatment of verruca vulgaris in general practice – a randomized controlled trial on the effectiveness of liquid nitrogen and the Histo-freeze. *J Dermatol Treat* 1992; **3**: 193–196.

7 Robson K, Cunningham NM, Kruzan KL. Pulsed dye laser versus conventional therapy for the treatment of warts: a prospective randomized trial. *J Am Acad Dermatol* 2000; **43**: 275–280.

8 Bunney MH, Nolan MW, Buxston PK, *et al.* The treatment of resistant warts with intralesional bleomycin: a controlled clinical trial. *Br J Dermatol* 1984; **111**: 197–207.

9 Bunney MH. The treatment of plantar warts with 5-fluorouracil. *Br J Dermatol* 1973; **89**: 96–97.

10 Berman B, Davis-Reed L, Silverstein L, *et al.* Treatment of verruca vulgaris with alfa2 interferon. *J Infect Dis* 1986; **154**: 328–330.

11 Stahl D, Veien NF, Wulf HC. Photodynamic inactivation of virus wart; a controlled clinical trial. *Clin Exp Dermatol* 1979; **4**: 81–85.

12 Mary H, Williams D. An assessment of methods of treating warts by comparative treatment trials based on a standard design. *Br J Dermatol* 1976; **94**: 667–679.

13 Gibbs S, Harvey I, Sterling J, *et al.* Local treatments for cutaneous warts: systematic review. *Br Med J* 2002; **325**: 461.

14 Fraker P, Gershwin E, Good A, *et al.* Interrelationships between zinc and the immune function. *Fed Proceed* 1986; **45**: 1474–1478.

15 Al-Gurairi F, Al Waiz M, Sharquie K. Oral zinc sulfate in the treatment of recalcitrant warts: randomized placebo-controlled clinical trial. *Br J Dermatol* 2002; **146**: 423–431.

16 Mancino P, Roma B, Onorati E, *et al.* Can self application of zinc sulfate and usnic acid cream improve the outcome of vulvoperineal HPV infection? *Gazz Med Ital Arch Sci Med* 2002; **161**: 177–181.

17 Tagami H, Oku T, Iwatsuki K. Primary tissue culture of spontaneously regressing flat warts: in vitro attack by mononuclear cells against wart-derived epidermal cells. *Cancer* 1985; **55**: 2437–2441.

18 Pace JSW, Russell BA, Torres HM, *et al.* Recombinant mouse gamma-interferon induces the priming step in macrophage activation for tumor cell killing. *J Immunol* 1983; **130**: 2011–2013.

19 Edwards L, Ferenczy A, Eron L, *et al.* Self-administered topical 5% imiquimod cream for external anogenital warts. *Arch Dermatol* 1998; **134**: 25–30.

20 Johnson R. Hypnosis, suggestion, and dermatologic changes: a consideration of the production and diminution of dermatologic entities. In: Spanos NP, Chaves JF, eds. *Hypnosis: Cognitive–Behavioral Perspectives*. Buffalo, NY: Prometheus, 1989: 297–312.

